



**Australian Government**  
**Department of Health and Ageing**



Australia and New Zealand Horizon Scanning Network

**ANZHSN**

AN INITIATIVE OF THE NATIONAL, STATE AND  
TERRITORY GOVERNMENTS OF AUSTRALIA  
AND THE GOVERNMENT OF NEW ZEALAND

# **Horizon Scanning Technology Prioritising Summary**

## **Breast tomosynthesis: a breast cancer screening tool**

**August 2008**



© Commonwealth of Australia 2008

ISBN

Publications Approval Number:

This work is copyright. You may download, display, print and reproduce this material in unaltered form only (retaining this notice) for your personal, non-commercial use or use within your organisation. Apart from any use as permitted under the *Copyright Act 1968*, all other rights are reserved. Requests and inquiries concerning reproduction and rights should be addressed to Commonwealth Copyright Administration, Attorney General's Department, Robert Garran Offices, National Circuit, Canberra ACT 2600 or posted at <http://www.ag.gov.au/cca>

Electronic copies can be obtained from <http://www.horizonscanning.gov.au>

Enquiries about the content of the report should be directed to:

HealthPACT Secretariat  
Department of Health and Ageing  
MDP 106  
GPO Box 9848  
Canberra ACT 2606  
AUSTRALIA

**DISCLAIMER:** This report is based on information available at the time of research cannot be expected to cover any developments arising from subsequent improvements health technologies. This report is based on a limited literature search and is not a definitive statement on the safety, effectiveness or cost-effectiveness of the health technology covered.

The Commonwealth does not guarantee the accuracy, currency or completeness of the information in this report. This report is not intended to be used as medical advice and intended to be used to diagnose, treat, cure or prevent any disease, nor should it be used therapeutic purposes or as a substitute for a health professional's advice. The Commonwealth does not accept any liability for any injury, loss or damage incurred by use of or reliance the information.

The production of this Horizon scanning prioritising summary was overseen by the Health Policy Advisory Committee on Technology (HealthPACT), a sub-committee of the Medical Services Advisory Committee (MSAC). HealthPACT comprises representatives from departments in all states and territories, the Australia and New Zealand governments; and ASERNIP-S. The Australian Health Ministers' Advisory Council (AHMAC) supports HealthPACT through funding.

This Horizon scanning prioritising summary was prepared by Linda Mundy and Professor Janet Hiller from the National Horizon Scanning Unit, Adelaide Health Technology Assessment, Discipline of Public Health, School of Population Health and Clinical Practice, Mail Drop 545, University of Adelaide, Adelaide, SA, 5005.

# PRIORITISING SUMMARY

**REGISTER ID:** 000373  
**NAME OF TECHNOLOGY:** BREAST TOMOSYNTHESIS  
**PURPOSE AND TARGET GROUP:** BREAST CANCER SCREENING TOOL

**STAGE OF DEVELOPMENT (IN AUSTRALIA):**

- |   |   |
|---|---|
| <input checked="" type="checkbox"/> Yet to emerge | <input type="checkbox"/> Established  |
| <input type="checkbox"/> Experimental             | <input type="checkbox"/> Established <i>but</i> changed indication or modification of technique |
| <input type="checkbox"/> Investigational          | <input type="checkbox"/> Should be taken out of use   |
| <input type="checkbox"/> Nearly established       |   |

**AUSTRALIAN THERAPEUTIC GOODS ADMINISTRATION APPROVAL**

- |   |             |
|---|-------------|
| <input type="checkbox"/> Yes            | ARTG number |
| <input checked="" type="checkbox"/> No  |             |
| <input type="checkbox"/> Not applicable |             |

Tomosynthesis is not approved for use by the Australian TGA or the United States FDA, however, a number of digital mammography units, which may be modified for tomosynthesis, have approval. Computed radiographic systems can not be upgraded to perform tomosynthesis, however direct flat panel detectors may be upgraded. Two direct flat panel detectors are listed on the TGA: the Hologic Lorad Selenia™ which is distributed by Medi-Consumables Pty Ltd and Insight Oceana Pty Ltd (ARTG numbers 99194 and 100125, respectively); and the Novation DR, distributed by Siemens Ltd (ARTG 99143). In addition, GE Healthcare Australia Pty Ltd distribute the Senographe 2000D, an indirect flat panel detector (ARTG number 111376) which is also capable of being upgraded to perform tomosynthesis.

**INTERNATIONAL UTILISATION:**

COUNTRY	LEVEL OF USE		
	Trials Underway or Completed	Limited Use	Widely Diffused
United States	✓		

**IMPACT SUMMARY:**

In April 2008 digital mammography was recommended for public funding as a screening test for breast cancer in asymptomatic women aged over 40 years or women at high risk; and for the investigation of women with symptoms of breast cancer. The purchase of “high-end” digital mammography equipment may allow further

modifications including the development of 3D imaging technology such as tomosynthesis.

## BACKGROUND

Normal breast tissue or overlapping tissue may obscure malignancies during conventional mammography. In addition to obscuring malignancies, normal tissue may mimic abnormalities by the summation of their radiographic attenuations, contributing to an increase in the number of false positives. Women with a suspect mammographic finding need to undergo diagnostic follow-up which may include further imaging and biopsy. Follow-up may be stressful for the patient and also contributes to increased health care costs. Digital breast tomosynthesis (DBT) may improve the diagnostic accuracy of mammography by reducing or eliminating artefacts produced by tissue overlap. DBT may also be particularly useful for women with dense breast tissue (Park et al 2007; Rafferty 2007).

In conventional mammography, the X-ray source remains stationary and X-rays are passed through the compressed breast tissue, absorbed by a phosphor screen to create an image on film. DBT is a modification of a digital mammography unit which allows the three dimensional (3D) acquisition of images. With DBT, the X-ray source moves along in a prescribed direction, usually an arc. Although each individual exposure is low dose, the composite dose during tomosynthesis is comparable, or higher (1.5 times the dose), to the dose incurred during a *single-view* mammogram (Figure 1 Image acquisition. Figure 1) (Park et al 2007; Rafferty 2007).

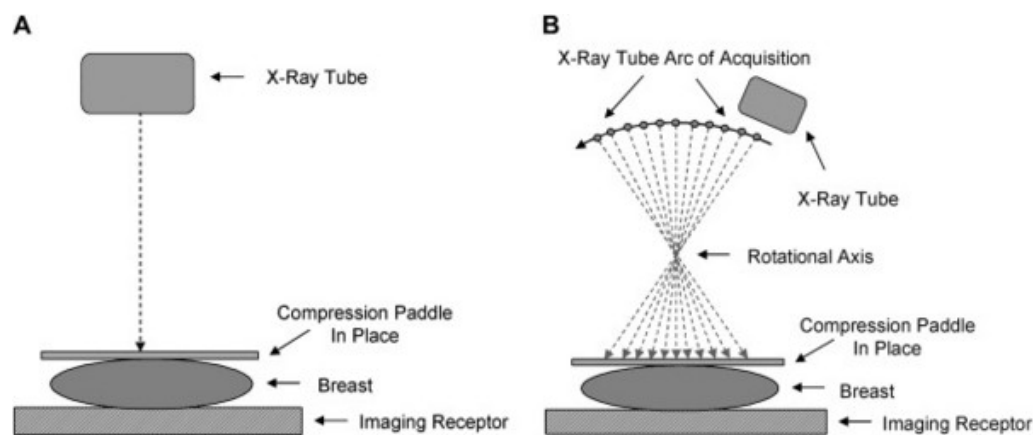


Figure 1 Image acquisition.  
A) Conventional mammography where the X-ray tube remains stationary  
B) DBT imaging where the X-ray tube traverses a proscribed arc acquiring a series of images (Rafferty 2007)

A high quality full-field, flat-panel digital detector is required to perform DBT. The detector can be made of either caesium iodide crystals on a silicon layer, or consist of selenium alone. The detector itself may be stationary or may move with the X-ray source tube. A moving detector has a wider field of view. Acquisition of images may either be continuous, using short pulsed exposures taken during the continuous motion

of the X-ray source, or by using the step-and-shoot method, which takes one exposure at each position of the X-ray source between movements. The step-and-shoot method takes longer and may result in more image artefacts due to patient movement. Images are reconstructed using algorithms similar to those employed in the reconstruction of CT images (Park et al 2007; Rafferty 2007). The number of reconstructed sections of each breast is large with DBT and may range from 30-80 (Chan et al 2005).

Breast tomosynthesis like digital mammography is reproducible, has reduced image noise, consistent quality and digital image processing (Park et al 2007).

### CLINICAL NEED AND BURDEN OF DISEASE

In Australia, breast cancer is the most frequently diagnosed cancer among women. The number of females diagnosed with breast cancer was estimated to be 13,261 in 2006 and is predicted to rise to 14,800 in 2011 (AIHW & NBCC 2006). The incidence of breast cancer in females rose from 105.3 cases per 100,000 population in 1993 to 111.8 cases per 100,000 population in 2003 (AIHW 2007b). The increase over this ten year period reflects both an increasing underlying rate and increased early detection through mammographic screening (see Figure 2).

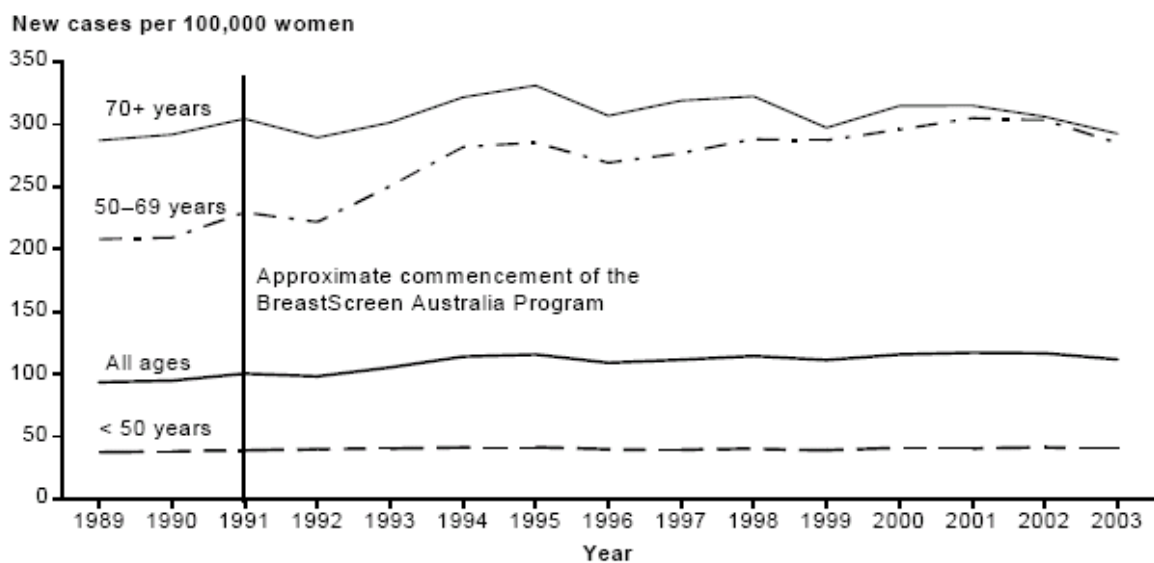


Figure 2 Incidence of breast cancer in women, Australia, 1989-2003 (AIHW 2007a)

Breast cancer is the most common cause of cancer-related death in Australian women, with 2,641 deaths attributed to breast cancer in 2004 (AIHW 2007a). However international comparisons of developed countries show that Australia has low mortality rates indicating good survival rates through early detection and treatment strategies (NBCC 2006). Age standardised mortality from breast cancer in women of all ages declined from 30.4 per 100,000 women in 1990 to 23.4 per 100,000 women in 2004 (AIHW 2007a). The five year survival rate of women whose breast cancer was diagnosed in 1998-2002 is 86.6 per cent across all ages with the highest survival rate

of 90.4 per cent apparent in women aged 60-69 years old. Ten-year relative survival increased by over 15 per cent from 57.5% for women diagnosed in 1982–1986 to 73.6% for women diagnosed in 1992–1997 (AIHW & NBCC 2006).

In 2001 there were 2,310 women with malignant breast cancer registered in New Zealand. As in Australia, the leading cause of death in New Zealand females is cancer, with breast cancer the leading cause of cancer death. During 2001 there were 615 deaths from malignant breast cancer amongst women in New Zealand (Weir et al 2007).

## **DIFFUSION**

Digital mammography has been approved for public funding in Australia, however digital breast tomosynthesis is not an approved technique and is currently undergoing clinical trials overseas.

## **COMPARATORS**

The current gold standard in Australia for breast cancer detection is the mammogram. In 1991 mammographic breast screening was introduced in Australia as a national program known as BreastScreen Australia. The program aims to provide mammographic screening at two-year intervals for asymptomatic women aged 50-69 years, however women aged 40-49 and over 70 years of age may attend free of charge (Forrest & Anderson 1999; National Breast Cancer Centre 2002). Mammographic examinations are available under the MBS (item numbers 59300 and 59303) for women with symptoms. In 2002-2003, more than 1.6 million Australian women aged between 50 and 69 years were screened as part of the BreastScreen Australia program. The participation rate for all Australian women in this target group was 56.1 per cent, slightly lower than the 56.9 per cent recorded in 2001-2002 (AIHW 2006). Current data suggests that screening 10,000 women aged 50-69 years of age, over 10 years, will prevent approximately 18 deaths, compared to preventing seven deaths in 10,000 women aged 40-49 years of age (National Breast Cancer Centre 2002).

The standard mammographic examination includes two sets of low-dose X-rays, one taken from the side (medio-lateral oblique) and one from the top view (cranio-caudal) resulting in a two-dimensional radiographic representation of the breast. The procedure takes approximately 20 minutes. Double readings of screening mammograms is mandatory in Australia (Forrest & Anderson 1999; President and Fellows of Harvard College 2003). The use of ionising radiation limits the age of patients who can undergo a mammogram and the frequency with which mammograms can be used. The radiation dose used for a mammogram will depend on the breast size, thickness and density of the tissue (Warren 2001). The initial mammogram serves as a baseline reference to enable the radiologist and clinicians to track any changes in the breast that may occur over time. On a mammogram of normal breast tissue, fat will appear as grey and the denser breast tissue as white. Abnormalities are

easier to identify in older, post-menopausal women as their breasts have proportionally greater amounts of fat. Mammography may not be as sensitive in older women who are taking hormone replacement therapy which may lead to denser breast tissue. Mammographic screening can detect cancer of the breast in its preclinical phase, detecting abnormalities as small as 5mm, which would not be detectable by palpation. Mammograms will detect microcalcifications, of which 80 per cent are harmless and will not lead to cancer. On finding an abnormality, the radiologist may recommend a repeat mammogram, additional magnified X-rays or a biopsy (Forrest & Anderson 1999; President and Fellows of Harvard College 2003).

Digital mammography also uses x-rays to produce images of the breast tissue but the x-ray photons encounter a solid state detector that converts the absorbed energy into an electrical signal (*directly*: radiation → electrical signal, or *indirectly*: radiation → light → electrical signal) (Dershaw 2006). These electrical signals are used to produce images of the breast that can be displayed on a computer monitor (soft copy) or be printed on laser film (hard copy). As digital mammography overcomes the interdependence between image acquisition, processing and image display associated with film-screen mammography, it allows these three characteristics to be individually manipulated and improved (Pisano & Yaffe 2005).

#### **SAFETY AND EFFECTIVENESS ISSUES**

The study by Poplack et al (2007) reported on the results of DBT conducted on 98 consecutive women (mean age  $57 \pm 11$  years), all of whom had been recalled due to an abnormal digital mammography result (level III-2 diagnostic evidence). DBT images were initially compared to the soft-copy digital mammogram, and were then examined in isolation to determine whether or not a recall was warranted. The quality of the DBT images were rated as equivalent (51/99<sup>1</sup>, 52%) or superior (37/99, 37%) to the quality of the soft-copy digital mammograms. The DBT image quality for the detection of *masses* was equivalent (5/19, 26%) or superior (13/19, 68%) when compared to soft-copy digital mammograms. However, the quality of DBT images was considered inferior to soft-copy digital mammograms in 57 per cent of cases (8/14) for the detection of *calcifications*. There were only 11 cases where the quality of DBT images were considered inferior, and the majority of these cases were due to calcification (8/11, 73%). If DBT was used in conjunction with digital mammography, the number of women recalled would have been reduced markedly (52/99, 52%)<sup>2</sup>. Follow-up imaging or pathology was conducted on 81/98 (83%) women. Nineteen of these women were recommended to undergo biopsy and five malignancies were detected in four women. Three of the five malignancies were detected by both DBT and digital mammography, and two were occult with both

---

<sup>1</sup> There were 99 breasts recalled in 98 women

<sup>2</sup> However, 7/99 (7%) of patients would *not* have been recalled by the study radiologist based on their digital mammograms and therefore the recall rate reduction should be 37/92 (40%)

techniques. Of the occult malignancies, one was a low grade DCIS<sup>3</sup> detected by MRI and the other was a mucinous cancer associated with DCIS which was detected incidentally by sonography. The authors suggest that although DBT has comparable or superior image quality to digital mammography, that DBT should be used in conjunction with digital rather than a stand alone technology (Poplack et al 2007). The study conducted by Good et al (2008) aimed to assess diagnostic performance issues associated with DBT (level III-2 diagnostic evidence). Nine radiologists were asked to independently assess a known<sup>4</sup> data set of images obtained with full-field digital mammography (FFDM), in addition to “frames”<sup>5</sup> obtained with DBT and reconstructed DBT images. Detection rates for each mode are summarised in Table 1. The recall rate was similar for all three modes for the non-malignant examinations (62.6-64.9%) and was considered to be relatively high. The actual recall rate for these non-malignant cases was 34 per cent. The recall rate for the malignant examinations was highest when DBT was used (93%) and lowest when only the DBT frames were used (79%). The proportion of malignant examinations recalled varied between readers. The detection rate for frames readers varied from 6/11 (55%) for one reader to 100 per cent. For DBT, one reader detected 9/11 (82%) malignancies, four readers detected 10/11 (91%) and the remaining four readers detected 100 per cent of malignancies. For FFDM, one reader detected 8/11 (73%), six readers detected 10/11 (91%) and the remaining two readers detected 100 per cent of malignancies. The effect of different reading modes on the proportion of either malignant or non-malignant recalls was not significant ( $p>0.05$ ), however this may be due to the small sample size.

Table 1 Summary of the overall detection/ recall rate for each mode

Mode	Non-malignant examinations		Malignant examinations	
	Frequency	% [95% CI]	Frequency	% [95% CI]
Frames	111	64.9 [57.7, 72.1]	79	79.8 [71.8, 87.9]
DBT	107	62.6 [55.3, 69.9]	93	93.9 [89.2, 98.8]
FFDM	110	64.3 [57.1, 71.6]	90	90.9 [85.2, 96.7]

DBT = digital breast tomosynthesis, FFDM = full-field digital mammography

The mean time spent reviewing images and rating the examination for different readers ranged from  $0.94 \pm 0.67$  to  $3.78 \pm 1.82$  minutes. The mean time for all readers for DBT was  $2.72 \pm 1.44$  minutes, compared to  $1.58 \pm 1.07$  and  $2.03 \pm 1.18$  minutes for FFDM and frames, respectively. There was a significant difference in the mean time taken for different readers ( $p= 0.0001$ ). The mean time to review and rate the examination was  $2.03 \pm 1.31$  minutes for the non-malignant images compared to  $2.52 \pm 1.37$  for the malignant images (NS,  $p>0.05$ ). The authors conclude that DBT may be

<sup>3</sup> DCIS = ductal carcinoma in situ

<sup>4</sup> The number of visible abnormalities (masses and calcifications) and the number of malignancies were already known

<sup>5</sup> Frames refers to the individual projection images before they have been reconstructed into one DBT image



a useful addition to breast screening but would benefit from the addition of CAD reading capabilities. In addition, substantial training of radiologists would be required to ensure accurate and efficient use of tomosynthesis as a screening tool (Good et al 2008).

### **COST IMPACT**

The approximate cost of the Hologic Lorad Selenia™ breast tomosynthesis unit is US\$ 650,000 or approximately A\$700,000 (personal communication Insight Oceana Pty Ltd).

### **ETHICAL, CULTURAL OR RELIGIOUS CONSIDERATIONS**

No issues were identified/raised in the sources examined.

### **OTHER ISSUES**

With the recent approval of public funding for digital mammography, this technology may supersede conventional mammography. “High-end” digital mammography units may be modified to allow the performance of tomosynthesis. This may be an important factor when investment decisions on the purchase of new digital mammography units are being considered by health authorities.

One of the major reasons that technologies such as digital mammography and tomosynthesis are entering into the Australian health system is the shortage of qualified radiologists and radiographers within Australia. This, in conjunction with the increasing demand for mammography, means that there is an imbalance in the supply and demand of mammography services.

The lead author of the Poplack et al (2007) paper is a member of the Scientific Advisory Board of Hologic Inc.

Several abstracts have been presented at recent meetings and it would be expected that these results should be published in the near future.

### **SUMMARY OF FINDINGS**

Only a few, small scale, poor quality studies have been published on the use of tomosynthesis for screening breast cancer. These studies were conducted on images which were likely to have a high number of positive readings. That is the images were obtained from a sample of patients who had been recalled due to a suspect mammogram or was a known positive, and are therefore likely to be biased. DBT performed well under these conditions compared to digital mammography, however it remains to be seen how DBT performs in a true screening environment where the number of true positive patients would be low. The two studies included in this summary reported high recall rates for negative images which may result in an increase in pathology and further imaging.

## **HEALTHPACT ACTION:**

Although only a low level of evidence was available to assess tomosynthesis for breast screening, it is likely that this technology will enter the Australian health system, especially in light of the roll out of digital mammography. Currently there is insufficient evidence to proceed with further assessment, therefore HealthPACT recommended that this technology be monitored.

## **NUMBER OF INCLUDED STUDIES**

Total number of studies

Level III-2 diagnostic evidence    2

## **REFERENCES:**

AIHW (2006). *BreastScreen Australia monitoring report 2002-2003*, Australian Institute of Health and Welfare, Canberra.

AIHW (2007a). *Breast Screen Australia monitoring report 2003-2004*, Australian Institute of Health and Welfare and the Australian Government Department of Health and Ageing for the Breast Screen Australia Program, Canberra.

AIHW (2007b). *Cancer in Australia: an overview, 2006*, AIHW (Australian Institute of Health and Welfare) & AACR (Australasian Association of Cancer Registries), Canberra.

AIHW & NBCC (2006). *Breast cancer in Australia: an overview, 2006*, Australian Institute of Health and Welfare and National Breast Cancer Centre, Canberra.

Chan, H. P., Wei, J. et al (2005). 'Computer-aided detection system for breast masses on digital tomosynthesis mammograms: preliminary experience', *Radiology*, 237 (3), 1075-1080.

Dershaw, D. (2006). 'Status of Mammography after the Digital Mammography Imaging Screen Trial: Digital versus Film', *The Breast Journal*, 12 (2), 99-102.

Forrest, A. P. & Anderson, E. D. (1999). 'Breast cancer screening and management', *Medical Journal of Australia*, 171 (9), 479-484.

Good, W. F., Abrams, G. S. et al (2008). 'Digital breast tomosynthesis: a pilot observer study', *AJR Am J Roentgenol*, 190 (4), 865-869.

National Breast Cancer Centre (2002). *Breast imaging: a guide for practice*, National Breast Cancer Centre, Sydney.

NBCC (2006). *Advice about familial aspects of breast and epithelial ovarian cancer: a guide for health professionals*, National Breast Cancer Centre, Sydney.

Park, J. M., Franken, E. A., Jr. et al (2007). 'Breast tomosynthesis: present considerations and future applications', *Radiographics*, 27 Suppl 1, S231-240.

Pisano, E. D. & Yaffe, M. J. (2005). 'Digital mammography', *Radiology*, 234 (2), 353-362.

Poplack, S. P., Tosteson, T. D. et al (2007). 'Digital breast tomosynthesis: initial experience in 98 women with abnormal digital screening mammography', *AJR Am J Roentgenol*, 189 (3), 616-623.

President and Fellows of Harvard College (2003). 'Update on breast imaging. New imaging techniques have led to advances in breast cancer detection. What does that mean for the annual mammogram?' *Harvard Womens Health Watch*, 10 (10), 4-6.

Rafferty, E. A. (2007). 'Digital mammography: novel applications', *Radiol Clin North Am*, 45 (5), 831-843, vii.

Warren, R. (2001). 'Screening women at high risk of breast cancer on the basis of evidence', *European Journal of Radiology*, 39 (1), 50-59.

Weir, R., Day, P. & Ali, W. (2007). *Risk factors for breast cancer in women*, New Zealand Health Technology Assessment.

**SEARCH CRITERIA TO BE USED:**

Breast Neoplasms/\*radiography/therapy

Female

Image Processing, Computer-Assisted/\*methods

Mammography/\*methods

Radiographic Image Enhancement/\*methods

Radiographic Image Interpretation, Computer-Assisted/methods

Tomography, X-Ray